MANAGING WOUNDS ASSOCIATED WITH PYODERMA GANGRENOSUM WITH ACTIVE LEPTOSPERMUM HONEY

Elizabeth A. George, RN, ET, CWON
Nason Hospital, Roaring Spring, PA

INTRODUCTION

Pyoderma Gangrenosum (PG) is an uncommon ulcerative condition with systemic diseases. Diagnosis is by exclusion. Ulcers heal very slowly. In a process called pathergy, new ulcerations may occur after trauma or injury, therefore sharp debridement is contraindicated.[1] Treatment consists of a combination of systemic and local care. The most consistent effective results are with corticosteroids and cyclosporin. Wound care should manage exudate, protect from trauma, maintain a moist wound environment and control pain. Non-adhesive dressings are preferred to decrease pain.

This patient suffers from Myelodysplastic Syndrome (MDS), a disorder in which the bone marrow does not produce enough healthy blood cells. Symptoms of MDS are related to low blood counts and are commonly treated with supportive care that includes blood transfusions and erythropoietis (stimulating agents).

The use of Dakin's solution denatures protein which loosens slough facilitating easier removal of the devitalized tissue. It is used to cleanse, debride,disinfect and control odor. Dakin's should be a short term treatment.

Active *Leptospermum* Honey* (ALH) strong osmotic action has demonstrated the ability to promote autolysis by pulling fluid from surrounding tissues thus bathing and cleansing slough and necrosis from the wound. ALH also has a naturally low pH (3.5-4.5) which can assist in lowering the pH of the wound environment. This reduction can enable the body's natural processes to overcome imbalances in the wound bed such as overactive protease activity - the by-product of which is slough and necrosis.

PURPOSE

To demonstrate the use of ALH for the treatment of challenging PG and the ease of administration.

METHODOLOGY

The patient is a 69 year old male who never missed a day's work despite the diagnosis of MDS. He was admitted to our rural hospital two weeks after injuring his right leg while chopping wood. His condition deteriorated after surgical debridement was performed on what was thought to be an abscess. He was transferred to a large metropolitan hospital and was diagnosed with a severe case of PG. He was initially treated with high doses of steroids and antibiotics, which stopped the progression of the disease but did not ease the pain. The wound was covered with yellow slough and dry eschar and involved his entire leg below the knee. Daily home visits were started by our home health agency. MD orders were to keep the area dry. Dakins soaks were used to keep the area hydrated and decrease bioburden. ALH was ordered due to its ability to assist with autolytic debridement and ease of use for the patient and his family. ALH was impregnated into Vaseline gauze and applied to the area, follow by a compression wrap. Shortly after the ALH was started, heavy rains washed out the bridge to his home and home health nurses were unable to visit. The family, including a son with a learning disability, assumed responsibility for his wound care.

RESULTS

After 6 months of treatment with ALH the wound was fully epithelialized. The high osmotic effect and low pH of ALH enabled complete cleansing of devitalized tissue and conversion from a wound in chaos (eg. overactive proteases producing slough tissue) to a wound in repair. As the healing progressed, the patient reported a decrease in pain associated with the PG.

CONCLUSION

A cooperative effort with hospital, home care, dermatologist, oncologist and family and the use of ALH resulted in full resolution for a very complicated case of Pyoderma Gangrenosum.

4/20/14

Home Health visits initiated. Wound on right lower leg was circumferential, measuring 22.8cm x 25cm x 2.0cm. Tissue was a dry eschar, yellow slough and very painful. Orders were to keep wound dry. Dakin's soaked gauze and compression wraps were applied. A call to a local dermatologist was made. He agreed with treatment to add a steroid ointment to peri-wound. Daily visits were started.

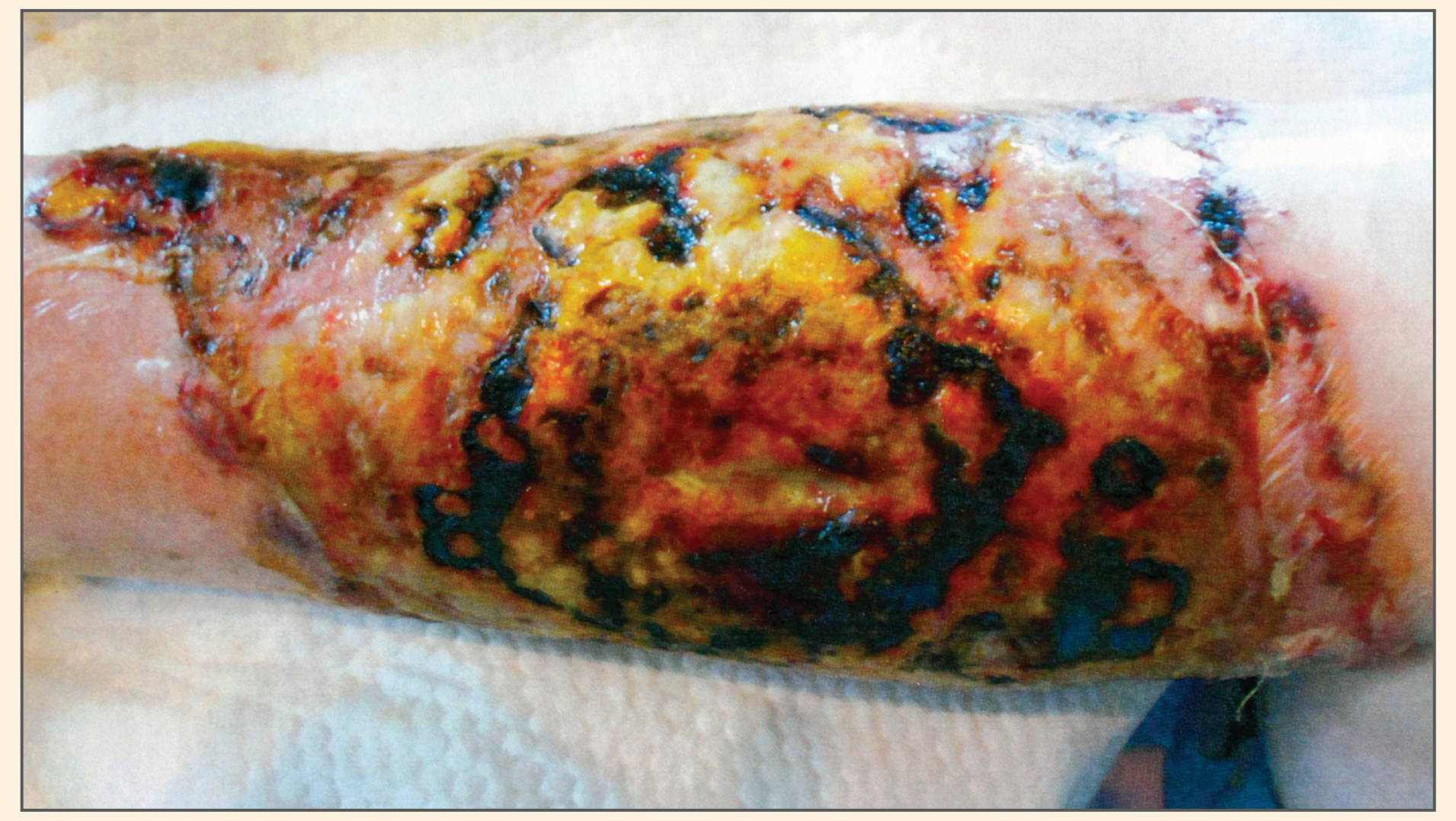

5/13/14

The dermatologist approved autolytic debridement with ALH because of its ease of use and lack of side affects. We applied the ALH Gel to vaseline gauze, then covered with absorptive gauze and compression wraps to control edema.

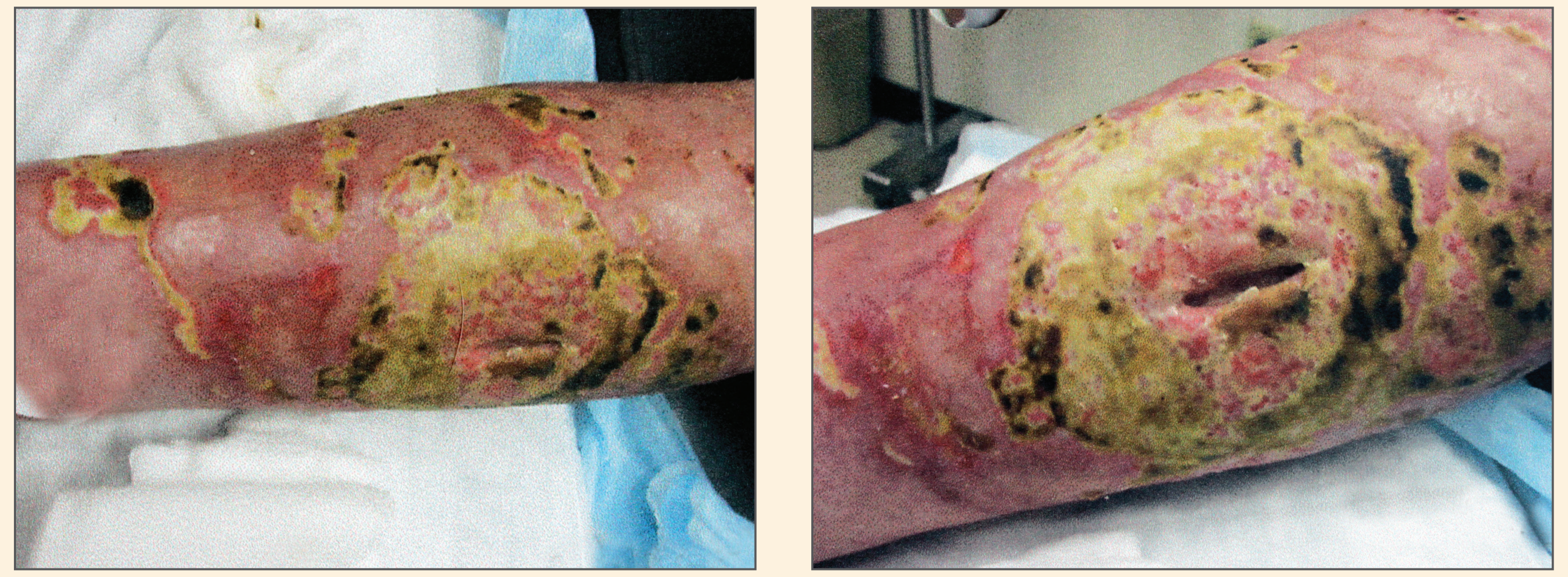

5/29/14

Wound was 50% debrided. Patient reported a decrease in pain with the ALH.

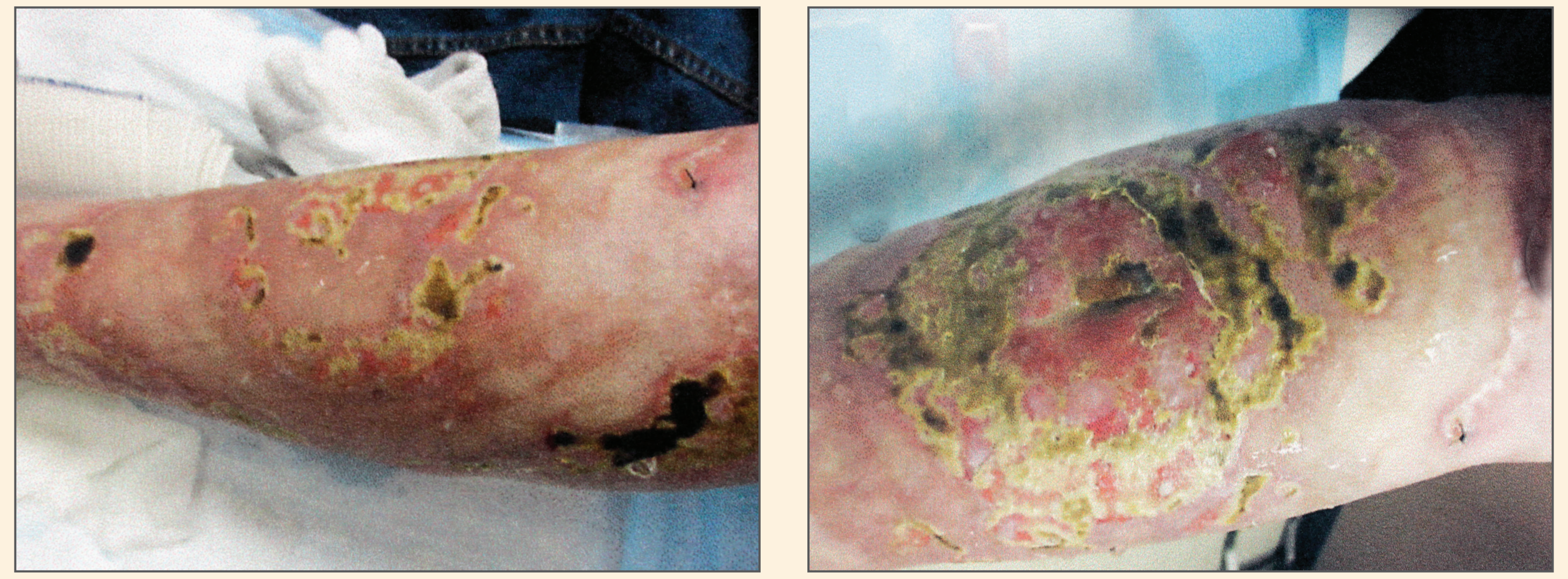

06/17/14

Flood waters have washed out the bridge to patients home and home health is no longer able to visit. Family drives through fields to reach the clinic. There has been concern with the family providing wound care. The home has less than ideal conditions. Patient's wife is physically disabled and the son has a learning disability. The son was instructed on how to perform wound care with ALH. The ALH was easy to use and there was no fear of misusing the product. They were advised to boil the water when cleansing the wound. Return visits revealed no problem with wound care.

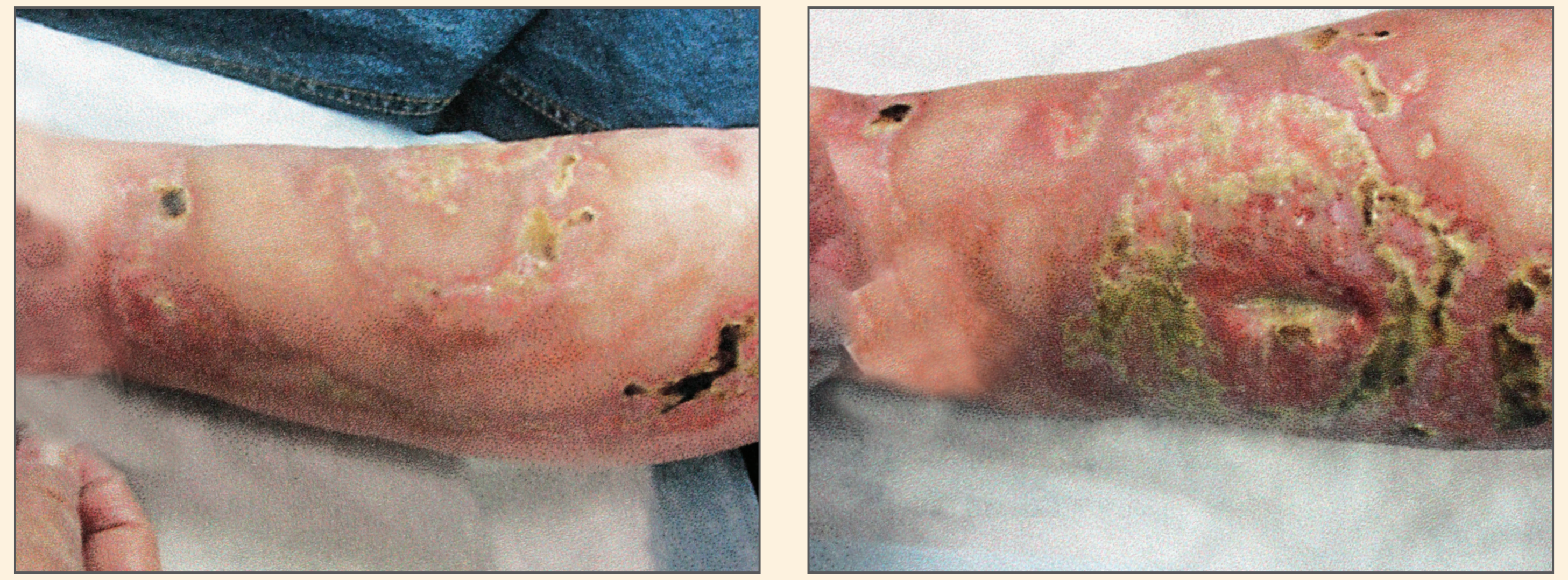

07/24/14

Patient visits were weekly, then every other week and alternate visits with the dermatologists. His medication was reviewed each visit. He would sometimes have his own variations on his medication. His blood work is monitored weekly by the oncologist for his MSD.

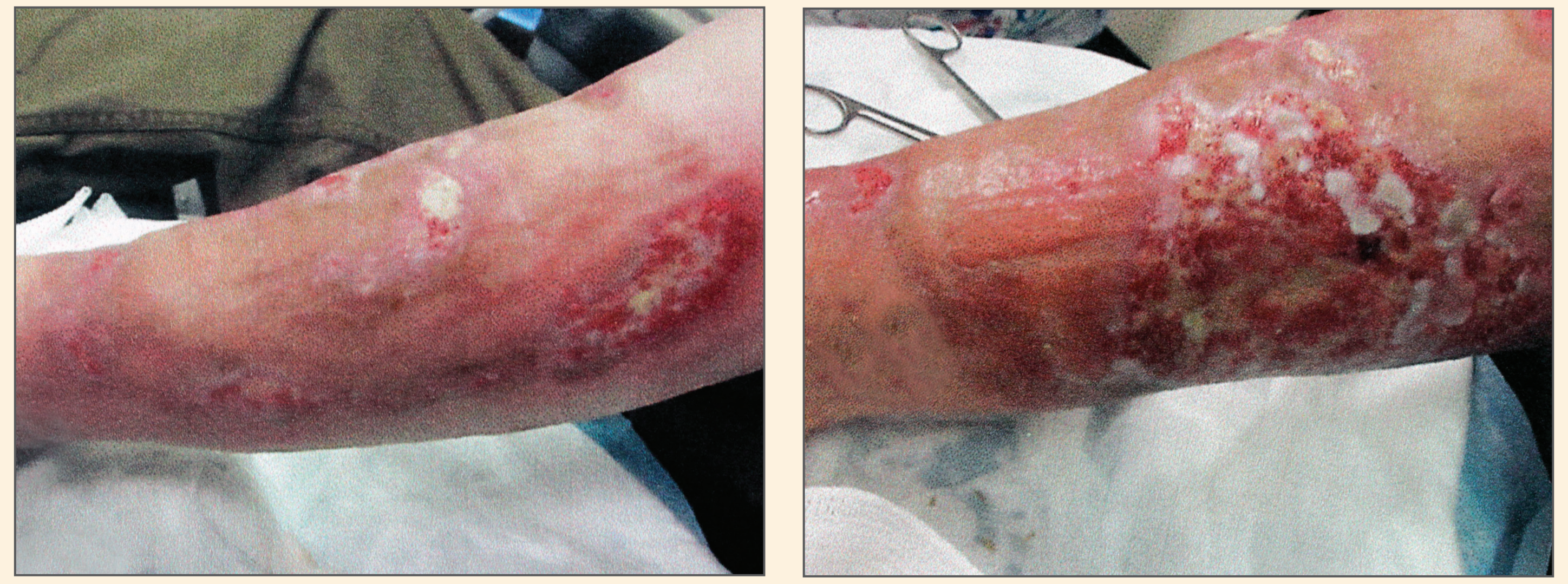

08/27/14

Wound continued to epithelialize and patient reported pain was greatly reduced.

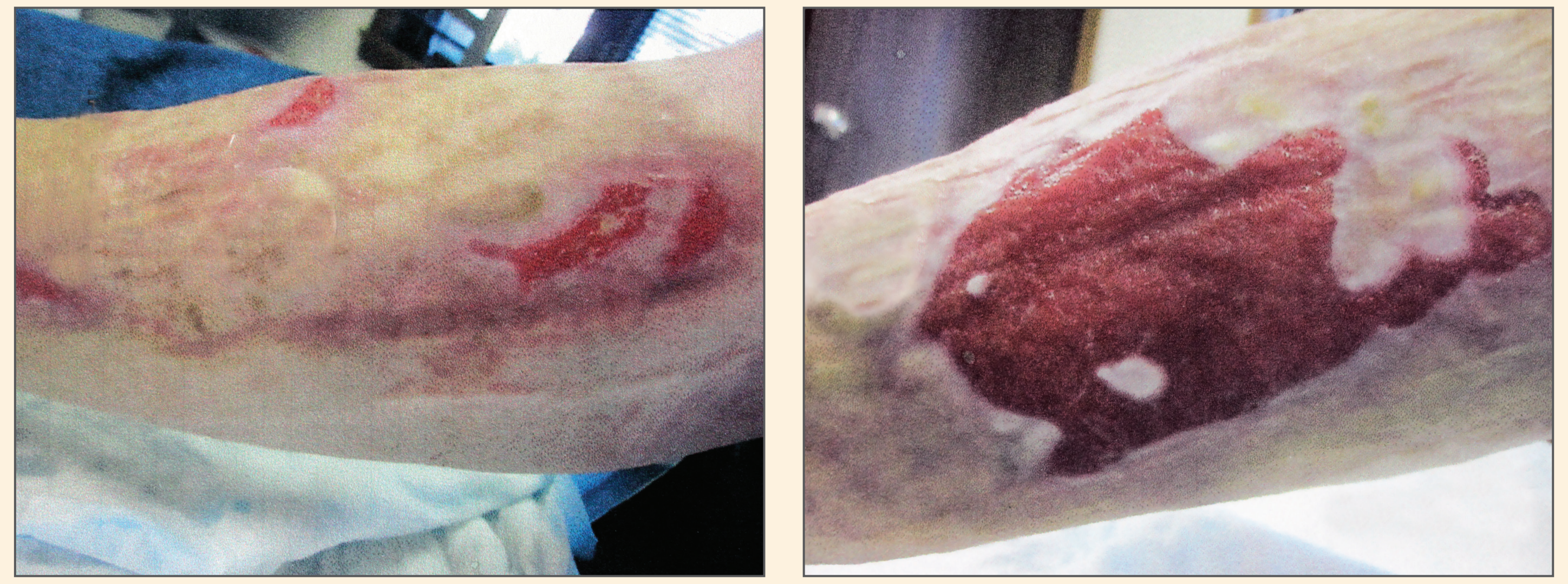

9/24/14

The lateral wound closed. There had been no change in wound care. Patient blood count remained stable.

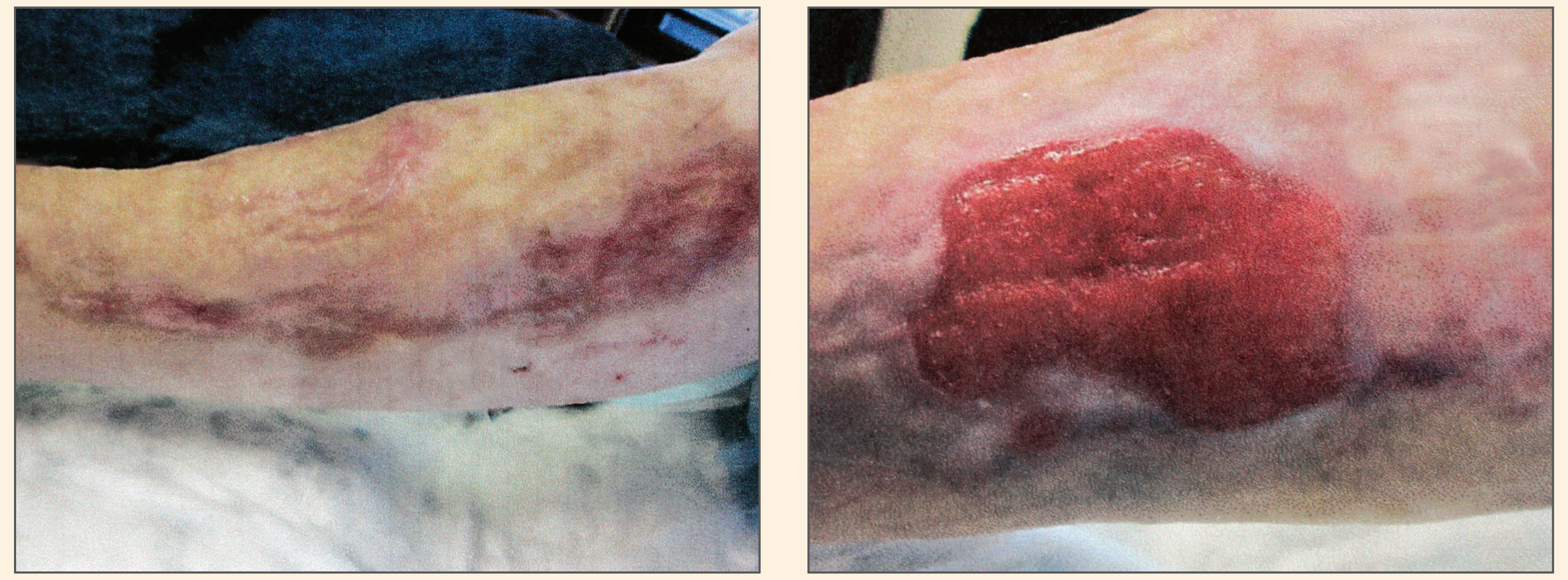

10/8/14

Wounds continue to close with no complications.

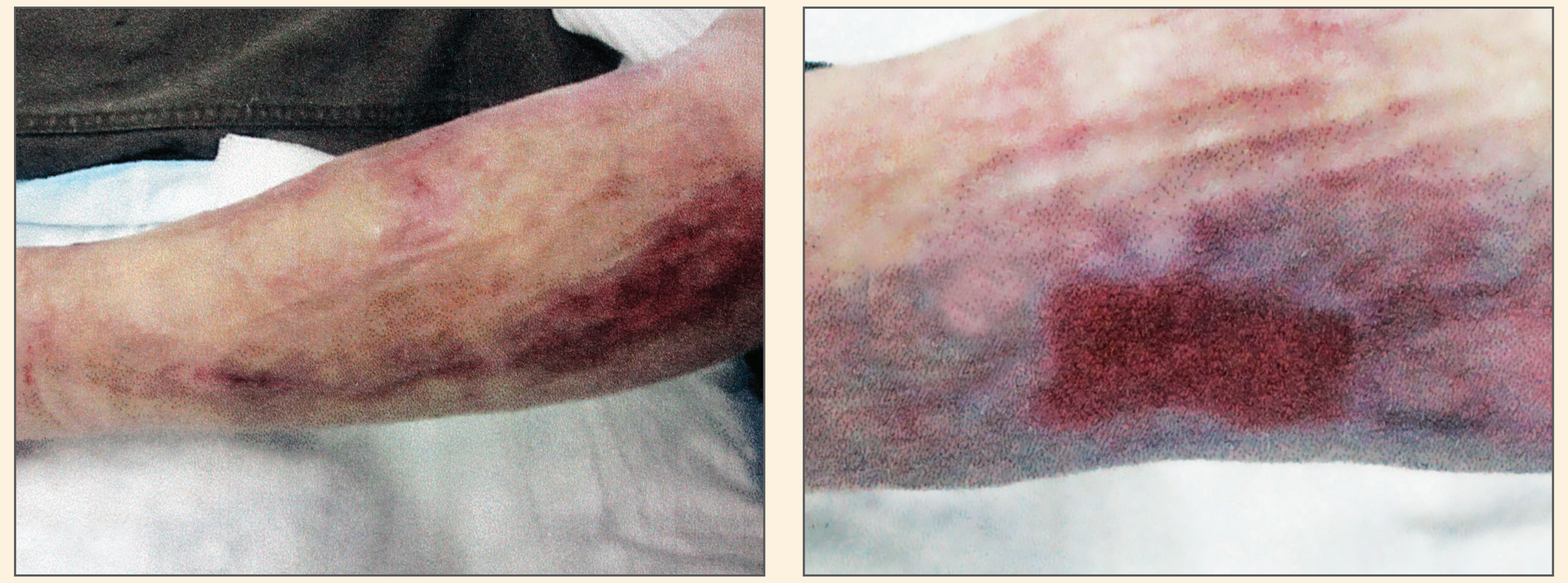

11/19/14

Wound closed. Patient was instructed to keep skin well moisturized. He was discharged from the wound clinic to be followed closely by his family doctor and dermatologist.

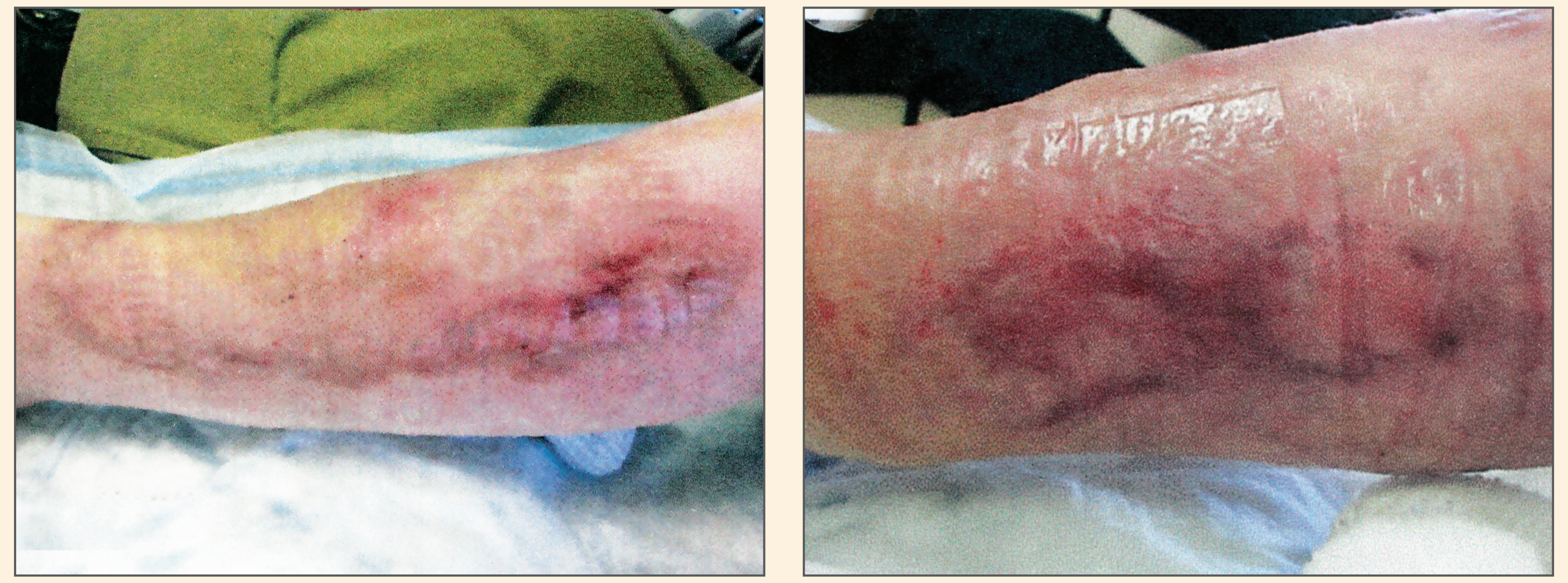

---

*MEDIHONEY® Active Leptospermum Honey Dressings, Derma Sciences, Inc., Princeton, NJ

References: 1. Bhat RM. Pyoderma gangrenosum: An update. Indian Dermatology Online Journal. 2012;3(1):7-13. 2.Molan PC. Re-introducing honey in the management of wounds and ulcers—theory and practice. Ostomy Wound Manage. 2002;48:28-40.

Derma Sciences provided an educational grant to support this research. The information may include a use that has not been approved or cleared by the Food and Drug Administration. This information is not being presented on behalf of Derma Sciences.

Poster content was updated from poster originally presented at WOCN 2015