

ORIGINAL ARTICLE

Manuka honey-impregnated dressings in the treatment of neuropathic diabetic foot ulcers

Alexandros V. Kamaratos¹, Konstantinos N. Tzirogiannis¹, Stella A. Iraklianiou¹, Georgios I. Panoutsopoulos², Ilias E. Kanellos¹ & Andreas I. Melidonis¹

¹ Diabetes Center, Tzanio General Hospital, Piraeus, Greece

² Department of Nursing, University of Peloponnese, Orthias Artemidos and Plateon, Sparta, Lakonia, Greece

Key words

Dressings; Manuka honey; Neuropathic diabetic foot ulcers

Correspondence to

Dr GI Panoutsopoulos, Department of Nursing, University of Peloponnese, Orthias Artemidos and Plateon, Sparta, Lakonia 23100, Greece
E-mail: geopanouts@gmail.com

doi: 10.1111/j.1742-481X.2012.01082.x

Kamaratos AV, Tzirogiannis KN, Iraklianiou SA, Panoutsopoulos GI, Kanellos IE, Melidonis AI. Manuka honey-impregnated dressings in the treatment of neuropathic diabetic foot ulcers. *Int Wound J* 2014; 11:259–263

Abstract

In this study, we investigate the effect of manuka honey-impregnated dressings (MHID) on the healing of neuropathic diabetic foot ulcers (NDFU). A total of 63 Caucasians, type 2 diabetic patients followed up in the diabetic foot outpatient clinic comprised the study population. Patients were randomised in two groups as follows: group I patients were treated with MHID and group II patients were treated with conventional dressings (CD). The patients were followed up on a weekly basis for 16 weeks. Mean healing time was 31 ± 4 days in group I versus 43 ± 3 days in group II ($P < 0.05$). In group I patients 78.13% of ulcers became sterile during the first week versus 35.5% in group II patients; the corresponding percentages for weeks 2, 4 and 6 were 15.62% versus 38.7%, 6.25% versus 12.9% and 0% versus 12.9% respectively. The percent of ulcers healed did not differ significantly between groups (97% for MHID and 90% for CD). MHID represent an effective treatment for NDFU leading to a significant reduction in the time of healing and rapid disinfection of ulcers.

Introduction

Medicinal properties of honey have been known for millenniums and have been used for the treatment of a variety of pathological conditions (1). The healing properties of honey have also been known from long and recently there has been a resurgence of interest about the ability of this natural product to assist wound healing with numerous reports in the international bibliography (2).

As a wound dressing, honey provides a moist environment with antimicrobial properties, has anti-inflammatory effects, reduces oedema and exudates, promotes angiogenesis and granulation tissue formation, induces wound contraction, stimulates collagen synthesis, facilitates debridement and accelerates wound epithelialisation (2–6). Honey efficacy in the healing of skin ulcers of different aetiologies has been documented in numerous studies (7).

Antibacterial action of honey has been attributed to its hyperosmolarity, acidity or other properties that have not been fully elucidated (8). Hydrogen peroxide is produced upon dilution of honey (9) by the enzymatic activity of oxidases

Key Messages

- the effect of manuka honey-impregnated dressings in the healing of neuropathic diabetic foot ulcers was investigated in a prospective, randomized, double blinded, with a control group study
- 63 diabetic patients with lower limb neuropathic diabetic foot ulcers comprised the study population
- 32 patients were treated with manuka honey-impregnated dressings and 31 with saline soaked dressings
- patients were followed up on weekly for 16 weeks
- swab cultures were also taken from all patients on a weekly basis
- manuka honey-impregnated dressings accelerated wound healing and disinfection of ulcers while percentage of ulcers healed was not affected
- manuka honey-impregnated dressings also nullified the need for antibiotics and hospitalization of patients with neuropathic diabetic foot ulcers

added in the nectar by bees (10), and it has been suggested to be the major antibacterial factor in at least some kind of honey. Apart from being an antiseptic H₂O₂ stimulates macrophage chemotaxis, induces Vascular Endothelial Growth Factor (VEGF) expression at the transcriptional level and consequently promotes angiogenesis and stimulates fibroblast proliferation while also possessing antioxidant action, protecting the local wound milieu from oxidative stress (11–13).

Honey also exerts significant actions on the immune system, both innate and adaptive, stimulating cytokine production [TNF α , interleukin (IL)-1 β and IL-6] by monocytes (13) and inducing B- and T-lymphocyte proliferation (14). The induction of proinflammatory cytokines by honey has also been reported to contribute to its antibacterial activity (13).

The acidification of the alkaline environment of chronic non-healing ulcers by honey has also been proposed as another mechanism by which honey induces healing. Acidification inhibits protease activity, induces fibroblast proliferation and establishes an aerobic environment, all of which aid in the healing process (2).

Nitric oxide (NO) is an important mediator in inflammation, cell proliferation and immune response and is actively implicated in wound healing (15,16). NO metabolites contained in honey (17) and induction of NO production by honey in different body fluids (18) constitute another mechanism by which honey induces wound healing, given the antimicrobial and immunoregulatory actions of NO.

Manuka honey (MH) is a natural, monofloral honey produced from bees feeding on manuka (*Leptospermum scoparium*) plant which is endemic in parts of Australia and New Zealand. MH has been reported to exhibit antibacterial activity against a broad spectrum of bacteria including *Staphylococcus aureus* [including Methicillin-Resistant *Staphylococcus aureus* (MRSA)], *Pseudomonas aeruginosa* and vancomycin-sensitive and vancomycin-resistant *enterococci* (19–22). MH has been found to arrest cell-cycle progression and prevent cell division of *S. aureus* (23) and to induce cell disruption and lysis of *P. aeruginosa* cells (24). Methylglyoxal has been identified as the active antibacterial component of MH (25,26).

Diabetic foot ulcers are reported to occur in 15% of patients (with different frequencies between type I and II diabetic patients) with diabetes and to antedate 84% of all diabetes-related amputations (27,28). Peripheral neuropathy leading to unperceived trauma seems to be the major cause of diabetic foot ulcers with 45–60% of ulcers to be considered merely neuropathic and 45% of mixed, neuropathic and ischaemic aetiology (29,30). Lower extremity ulcers represent one of the most common complications of diabetes and a leading cause for hospitalisation of diabetic patients (31). Neuropathy, deformity, high plantar pressure, poor glycaemic control, long duration of diabetes, peripheral arterial disease, and male gender all are risk factors for lower extremity ulceration (27,31,32). Treatment of lower extremity ulcers imposes a huge burden on health care systems worldwide with at least 33% of all costs to treat diabetes complications to be spent for the treatment of ulcers (33).

MH has been reported to be effective in the treatment of leg ulcers of diverse aetiology (2,34,35) and is considered as honey with high antibacterial properties.

In this study, we investigate the effect of manuka honey-impregnated dressings (MHID) in the healing and microbiology of NDFU.

Materials and methods

This prospective randomised, controlled, double-blinded study was conducted in a tertiary Greek hospital. The study population consisted of 63 type II diabetic patients, male and female, with Wanger classification (31) grade 1 and 2 lower limb neuropathic ulcers. They were consecutive patients at the outpatient diabetic foot clinic. The patients were randomly assigned to two groups: group I ($n = 32$) patients were treated with MHID (Medihoney Tulle Dressing) and group II ($n = 31$) patients with conventional dressings (CD, saline-soaked gauze dressings). The first patient was enrolled in group I and the subsequent patients were enrolled between groups II and I in an alternating fashion. Exclusion criteria included allergy to honey or bee products, presence of end-stage renal disease on dialysis, concurrency of serious medical illness, chronic steroid treatment (defined as intake of corticosteroids of more than 2 weeks duration) and Ankle-Brachial Index (ABI) <0.9.

Meticulous debridement was conducted upon initial visit and when judged clinically necessary thereafter. The wound area was determined by multiplying the maximum perpendicular length of the ulcer with the greatest width recorded in centimetres upon initial visit. Measurements were performed in duplicate by two independent observers. Wound dressing was applied by qualified staff nurses initially on a daily basis and then with declining frequency as wound healing progressed. Preparation and application of dressings were performed by qualified nurses unaware of the study protocol. The patients were followed up for 16 weeks and they were all given instructions regarding ulcer care. Swab cultures were taken from all patients after wound debridement upon initial visit and then on a weekly basis. A charcoal swab stick was used which was placed immediately after swabbing in Stuart's transport medium and rapidly transferred to the microbiology department for aerobic and anaerobic cultures. Patients were followed up in the outpatient diabetic foot clinic by a distinct research team unaware of the study protocol.

The Perfusion, Extent/size, Depth/tissue loss, Infection, and Sensation (PEDIS) system (36) was used for the clinical evaluation and classification of wound infections. Initial empirical antibiotic therapy included monotherapy with trimethoprim-sulphamethoxazole, amoxicillin/clavulanate, ampicillin/sulbactam and levofloxacin for per os (PO) administration in patients with mild or moderate severity infections. Initial parenteral therapy for hospitalised patients with severe infections included monotherapy with piperacillin/tazobactam, imipenem/cilastatin, ertapenem and combinations of vancomycin or linezolid with ceftazidime and clindamycin or the combination of levofloxacin with clindamycin. Antibiotic treatment was modified according to swab culture results. Off-loading of the affected limb was applied in all patients.

The study protocol was approved by the institutional review board, and all patients provided written informed consent.

The study conformed to the ethical guidelines of the 1975 Declaration of Helsinki.

Statistical methods

Demographic and clinical data were described as mean \pm standard deviation for continuous variables. The normality assumption for each one of the two groups was tested with the Shapiro Wilk test (P -value >0.05). Comparisons between the groups were analysed by unpaired, two-tailed Student's t -test. Although a convenient sample was included in the study, post hoc power analysis concerning the null hypothesis of no differences among the mean value of the two groups, with G*Power (37) based on: $\alpha = 0.05$ and effect size $d = 3.39$, showed power >0.95 . All data were analysed using IBM SPSS for Windows v.20 software (IBM, New York, NY).

Results

Mean age of patients was 56 ± 14 years for group I and 57 ± 15 years for group II. Mean HbA1C was 10.9 ± 2.1 for group I and 11.2 ± 2.3 for group II ($P = 0.423$). Ninety-seven percent (31/32) of NDFU in the group of MHID healed during the follow-up period versus 90% (28/31) in the group of CD ($P = 0.4$). Mean duration of healing was 31 ± 4 days in the MHID group versus 43 ± 3 days in the CD group [$P < 0.05$, confidence interval (CI) 95% $-10.7N$ to -8.7] (Figure 1).

Swab cultures were positive for all patients of both groups upon initial visit (Figure 2). Swabs from 45 patients showed mixed growth (71.5%), 5 colonisation with pseudomonas (7.9%), 10 with *E. coli* (15.8%), 2 with methicillin resistant *S. aureus* (3.2%) and 1 with *Proteus sp.* (1.6%).

In MHID group of patients, 25 (78.13%) patients presented with sterile wounds within the 1st week, 5 (15.62%) within the 2nd week and the remaining 2 (6.25%) within 4 weeks. In group II of patients, 11 (35.5%) patients presented with sterile ulcers within the 1st week, 12 (38.7%) patients within 2 weeks, 4 (12.9%) patients within 4 weeks and the remaining 4 (12.9%) patients within 6 weeks.

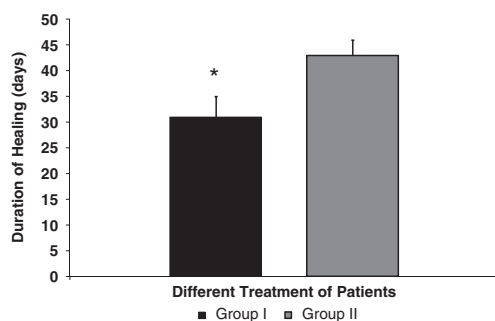


Figure 1 Duration of healing of neuropathic diabetic foot ulcers in diabetic type II patients treated with manuka honey-impregnated dressings (group I) and with conventional dressings (group II). Results represent the findings from 32 patients in group I and 31 patients in group II. Values are expressed as means \pm SD. * $P < 0.05$ group I versus group II.

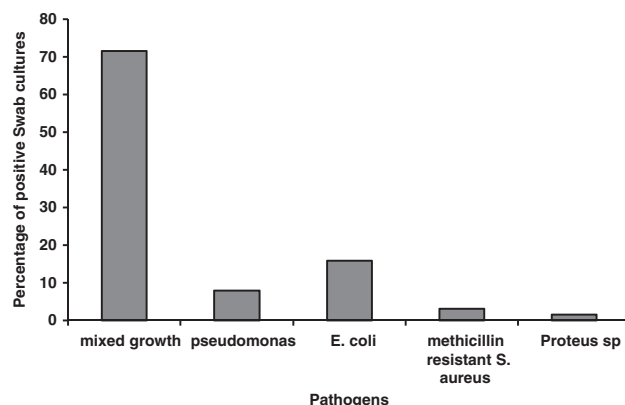


Figure 2 Cumulative swab culture results for patients treated with manuka honey-impregnated dressings and conventional dressings taken during their initial visit upon commencement of the study.

None of the patients in group I needed treatment with antibiotics, while 9 (29%) patients in group II needed antibiotic treatment during the follow-up period. Furthermore, four of these patients were hospitalised for 28 days.

Swab cultures from the five patients treated on an outpatient basis were positive for MRSA in two patients, Methicillin-Sensitive Staphylococcus aureus (MSSA) in one patient, *P. aeruginosa* in one patient and group B β -hemolytic streptococci in one patient. In the four hospitalised patients swab cultures were positive for MRSA in one patient, *P. aeruginosa* in one patient and vancomycin-resistant Enterococci in two patients with recent history of hospitalisation.

Discussion

In this study, we investigate the effect of MH on the healing of NDFU. MHID expedited ulcer healing in our study while there was also a trend for increased proportion of ulcers healed in MHID group which did not achieve statistical significance though. Our results are in agreement with those of previous studies on the effect of honey in general on diabetic foot ulcer healing (38–40) and further strengthen the clinical evidence for the widespread use of honey dressings at least in neuropathic diabetic foot ulcers (NDFU). More specifically, in relation to MH our results are also in agreement with previous reports of other researchers in which MH has proved effective in the healing of venous leg ulcers (35,36,41,42), surgical wounds (43) and diverse wounds in pediatric hematology–oncology patients (44). It should be noted though that in the majority of the above studies diabetic patients have been excluded fact that underlines the need for future prospective randomised trials in order to fully elucidate the effect of MH in the healing of wounds in diabetics.

Methylglyoxal, the active antibacterial ingredient of MH, has been reported to react with lysine, arginine and cysteine residues of structural proteins, such as collagen, giving genesis to advanced glycation end products (AGEs) that disrupt extracellular matrix remodeling, promote fibrosis in chronic tissue infections, impair immune response and microcirculation, promote atherosclerosis and neovascularisation,

induce endothelial cell dysfunction and impair wound closure (45,46). The above have raised concerns about a possible detrimental effect of methylglyoxal, and consequently MH, in the healing of diabetic foot ulcers (46). The results of this study showed expedition of healing of diabetic foot ulcers and do not support the above concerns. Further research with future randomised prospective clinical trials is needed in this field in order to fully elucidate MH honey effect on the healing of NDFU.

Application of MHID was accompanied by rapid clearance of ulcer bacterial load with nullification of the need for antibiotics and hospitalisation and the above are in agreement with the well-substantiated broad antibacterial activity of MH (21–24). Additionally, the repertoire of bacteria isolated from patients of the CD group that received antibiotic treatment, both on inpatient and outpatient basis, has yielded pathogens against which MH has been reported to be highly effective. More specifically, in hospitalised patients swab cultures have been positive for MRSA, *P. aeruginosa* and vancomycin-resistant *enterococci* where MH has been reported to be effective against these pathogens in numerous *in vitro* and *in vivo* clinical studies (21–24,47,48).

The results of this study conflict with those of Lund-Nielsen *et al.* (49) which showed no effect of MHID on wound pathogens in malignant wounds from patients with advanced neoplastic disease. Concurrence of severe disease, including cancer, has been an exclusion criterion in our study and the above discordant results should be attributed to the different population sample in the two studies. In the Lund-Nielsen *et al.* study, 81% of patients were receiving antineoplastic treatment and 16% antibiotic treatment during the study period. Additionally, malignant wounds were considered to progress because of their malignant nature and the action of chemotherapy fact that could cause significant necrosis and debris production while debridement was not included in the management of wounds. The above could be responsible for poor honey penetration and action and perpetuation of malignant wound microbiology. Another issue is the absence of control group in the above study as well as the absence of quantitative microbiological evaluation of bacterial load fact that could confound the results as the observed no qualitative difference does not exclude antibacterial effect of MH that might have been evident if bacterial load was found increased in the control group.

In economic terms, significant benefits ensued from the nullification of antibiotic need and necessity for hospitalisation and the above are important, given the financial burden that diabetic foot ulceration imposes on health care systems worldwide. Moreover, it should finally be noted that despite the previous history of hospitalisation during the last 3 months in five of patients in MHID group none needed antibiotics or hospitalisation, the fact that underlines the importance of MH as a potent disinfectant. Additional financial benefits also ensued from the shorter time of healing in MHID group of patients.

In conclusion, the results of this study strongly support the antibacterial effect of MH in NDFU, the fact that seems to lay in the basis of expedited wound healing observed.

Acknowledgement

The study was funded by the Diabetes Center Research fund.

References

1. Majno GA. *The healing hand: man and woman in the ancient world*. Cambridge: Harvard University Press, 1975.
2. Al-Waili N, Salom K, Al-Ghamdi AA. Honey for wound healing, ulcers and burns; data supporting its use in clinical practice. *ScientificWorldJournal* 2011;**11**:766–87.
3. Molan PC. The evidence supporting the use of honey as a wound dressing. *Int J Low Extrem Wounds* 2006;**5**:40–54.
4. Molan PC. The role of honey in the management of wounds. *J Wound Care* 1999;**8**:415–8.
5. Jull AB, Rodgers A, Walker N. Honey as a topical treatment for wounds. *Cochrane Database Syst Rev* 2008;**4**:CD005083.
6. Sharp A. Beneficial effects of honey dressings in wound management. *Nurs Stand* 2009;**24**:66–68.
7. Tovey FI. Honey and healing. *J R Soc Med* 1991;**84**:447.
8. Karayil S, Deshpande SD, Koppikar GV. Effect of honey on multidrug resistant organisms and its synergistic action with three common antibiotics. *J Prostgrad Med* 1998;**44**:93–6.
9. Bang LM, Bunting C, Molan P. The effect of dilution on the rate of hydrogen peroxide production in honey and its implications for wound healing. *J Altern Complement Med* 2003;**9**:267–73.
10. White JW Jr, Subers MH, Schepartz AI. The identification of inhibine, the antibacterial factor in honey, as hydrogen peroxide and its origin in a honey glucose-oxidase system. *Biochim Biophys Acta* 1963;**73**:57–70.
11. Yoo SK, Huttenlocher A. Innate immunity: wounds burst H₂O₂ signals to leukocytes. *Curr Biol* 2009;**19**:R553–5.
12. Cho M, Hunt TK, Hussain MZ. Hydrogen peroxide stimulates macrophage vascular endothelial growth factor release. *Am J Physiol Heart Circ Physiol* 2001;**280**:H2357–63.
13. Tonks AJ, Cooper RA, Jones KP, Blair S, Parton J, Tonks A. Honey stimulates inflammatory cytokine production from monocytes. *Cytokine* 2003;**21**:242–7.
14. Fukuda M, Kobayashi K, Hirono Y, Miyagawa M, Ishida T, Ejiogu EC, Sawai M, Pinkerton KE, Takeuchi M. Jungle honey enhances immune function and antitumor activity. *Evid Based Complement Altern Med* 2009;**6**:50–6.
15. Moncada S, Palmer RM, Higgs EA. Nitric oxide: physiology, pathophysiology and pharmacology. *Pharmacol Rev* 1991;**43**:109–42.
16. Childress B, Stechmiller K. Role of nitric oxide in wound healing. *Biol Res Nurs* 2002;**4**:5–15.
17. Al-Waili NS. Identification of nitric oxide metabolites in various honeys: effects of intravenous honey on plasma and urinary nitric oxide metabolites concentrations. *J Med Food* 2003;**6**:359–64.
18. Al-Waili NS, Saloom KY. Effects of topical honey on post-operative wound infections due to gram positive and gram negative bacteria following caesarian sections and hysterectomies. *Eur J Med Res* 1999;**4**:126–30.
19. Blair SE, Cokcetin NN, Harry E. The unusual antibacterial activity of medical-grade *Leptospermum* honey: antibacterial spectrum resistance and transcriptome analysis. *Eur J Clin Microbiol Infect Dis* 2009;**28**:1198–208.
20. George NM, Cutting KF. Antibacterial honey (Medihoney): *in vitro* activity against clinical isolates of MRSA, VRE, and other multiresistant Gram-negative organisms including *Pseudomonas aeruginosa*. *Wounds* 2007;**19**:231–6.
21. Sherlock O, Dolan A, Athman R, Power A, Gethin G, Cowman S, Humphreys H. Comparison of the antimicrobial activity of ulmo honey from Chile and manuka honey against methicillin-resistant *Staphylococcus aureus*, *Escherichia coli*, and *Pseudomonas aeruginosa*. *BMC Complement Altern Med* 2010;**10**:47.

22. Cooper RA, Molan PC, Harding KG. The sensitivity to honey of Gram-positive cocci of clinical significance isolated from wounds. *J Applied Microbiol* 2002;**93**:857–63.
23. Henriques AF, Jenkins RE, Burton NF, Cooper RA. The intracellular effect of manuka honey on *Staphylococcus aureus*. *Eur J Microbiol Infect Dis* 2010;**29**:45–50.
24. Henriques AF, Jenkins RE, Burton NF, Cooper RA. The effect of manuka honey on the structure of *Pseudomonas aeruginosa*. *Eur J Microbiol Infect Dis* 2011;**30**:167–71.
25. Mavric E, Wittmann S, Barth G, Henle T. Identification and quantification of methylglyoxal as the dominant antibacterial constituent of manuka (*Leptospermum scoparium*) honeys from New Zealand. *Mol Nutr Food Res* 2008;**52**:483–9.
26. Adams CJ, Manley-Harris M, Molan PC. The origin of methylglyoxal in New Zealand manuka (*Leptospermum scoparium*) honey. *Carbohydr Res* 2009;**344**:1050–3.
27. Reiber GE, Vileikyte L, Boyko EJ, Del-Aguila M, Smith DG, Lavery LA, Boulton AJ. Causal pathways for incident lower-extremity ulcers in patients with diabetes from two settings. *Diabetes Care* 1999;**22**:157–62.
28. Reiber GE, Boyko EJ, Smith DG. Lower extremity foot ulcers and amputations in diabetes. In: Harris MI, Stern MP, editors. *Diabetes in America*. Bethesda: US government Printing Office, 1995:409–28.
29. Frykberg RG. Diabetic foot ulcers: pathogenesis and management. *Am Fam Physician* 2002;**66**:1655–62.
30. Akbari CM, Macsata R, Smith BM, Sidawy AN. Overview of the diabetic foot. *Semin Vasc Surg* 2003;**16**:3–11.
31. Wanger FW Jr. The diabetic Foot. *Orthopedics*, 1978;**10**:163–72.
32. Frykberg RG, Zgonis T, Armstrong DG, Driver VR, Giurini JM, Kravitz SR, Landsman AS, Lavery LA, Moore JC, Schuberth JM, Wukich DK, Andersen C, Vanore JV. Diabetic foot disorders. A clinical practice guideline (2006 revision). *J Foot Ankle Surg* 2006;**45**(5 Suppl):S1–66.
33. Driver VR, Fabbi M, Lavery LA, Gibbons G. The costs of diabetic foot: the economic case for the limb salvage team. *J Vasc Surg* 2010;**52**(3 Suppl):17S–22S.
34. Gethin G, Cowman S. Case series of use of manuka honey in leg ulceration. *Int Wound J* 2005;**2**:10–15.
35. Jull A, Walker N, Parag V, Molan P, Rodgers A. Randomized clinical trial of honey-impregnated dressings for venous leg ulcers. *Br J Surg* 2008;**95**:175–82.
36. Lipsky BA, Berendt AR, Deery GH, Embil JM, Joseph WS, Karchmer AW, LeFrock JL, Lew DP, Mader JT, Norden C, Tan JS. Diagnosis and treatment of diabetic foot infections. *CID* 2004;**39**:885–910.
37. Faul F, Erdfelder E, Lang A, Buchner A. G*Power 3: a flexible statistical power analysis program for the social, behavioral, and biomedical sciences. *Behav Res Methods* 2007;**39**:175–91.
38. Hammouri SK. The role of honey in the management of diabetic foot ulcers. *JRMS* 2004 ;**11**:20–2.
39. Moghazy AM, Shams ME, Adly OA, Abbas AH, El-Badawy MA, Elsakka DM, Hassan SA, Abdelmohsen WS, Ali OS, Mohamed BA. The clinical and cost effectiveness of bee honey dressing in the treatment of diabetic foot ulcers. *Diabetes Res Clin Pract* 2010;**89**:276–81.
40. Eddy JJ, Gideonsen MD. Topical Honey for diabetic foot ulcers. *J Fam Pract*, 2005;**54**:533–6.
41. Armstrong DG. Manuka honey improved wound healing in patients with sloughy venous leg ulcers. *Evid Based Med* 2009;**14**:148–52.
42. Robson V, Dodd S, Thomas S. Standardized antibacterial honey (Medihoney™) with standard therapy in wound care: randomized clinical trial. *J Adv Nurs* 2008;**18**:466–74.
43. Cooper RA, Molan PC, Krishmoorthy L, Harding KG. Manuka honey used to heal a recalcitrant surgical wound. *Eur J Clin Microbiol Infect Dis* 2001;**20**:758–9.
44. Simon A, Sofka K, Wiszniewsky G, Blaser G, Bode U, Fleischhack G. Wound care with antibacterial honey (Medihoney) in pediatric hematology-oncology. *Support Care Cancer* 2006;**14**:91–7; DOI: 10.1007/s00520-005-0874-8.
45. Goova MT, Li J, Kislinger T, Qu W, Lu Y, Bucciarelli LG, Nowygrod S, Wolf BM, Caliste X, Yan SF, Stern DM, Schmidt AM. Blockade of receptor for advanced glycation end-products restores effective wound healing in diabetic mice. *Am J Pathol* 2001;**159**:513–25.
46. Majtan J. Methylglyoxal - a potential risk factor of manuka honey in healing of diabetic ulcers. *Evid Based Complement Alternat Med* 2011;2011:295494.
47. Cooper RA, Molan PC, Harding KG. Antibacterial activity of honey against strains of *Staphylococcus aureus* from infected wounds. *J R Soc Med* 1999;**92**:283–5.
48. Cooper RA, Molan PC. The use of honey as an antiseptic in managing *Pseudomonas* infection. *J Wound Care* 1999;**8**:161–4.
49. Lund-Nielsen B, Adamsen L, Gottrup F, Rorth M, Tolver A, Kolmos JK. Qualitative bacteriology in malignant wounds – a prospective, randomized, clinical study to compare the effect of honey and silver dressings. *Ostomy Wound Manage* 2011;**57**:28–36.