

Authors:

Emmanuelle Candas, Geriatrician, Expert in Wound Management, Hôpital Ste Périne, Paris, France

Jan Forster, Wound Competence Center, Bremen, Germany

John Schäfer, Expert Nurse Consultant on Chronic Wounds, Institute for Health Services Research in Dermatology and Nursing (IVDP), University Medical Centre, Hamburg, Germany

François Sterpione, Nurse, Echirolles Infirmier, France

References

- Atkin L, Bucko Z, Montero EC et al (2019) Implementing TIMERS. *J Wound Care* 1(23): s1-50
- Atkin L, Ousey K (2016) Wound bed preparation. *Br J Community Nurs* 21(Sup 12): S23-8
- Mikosinski J, Kalogeropoulos K, Bundgaard L et al (2021) Longitudinal evaluation of biomarkers in wound fluids of venous leg ulcers treated with a protease-modulating wound dressing: A prospective study. Manuscript in preparation
- Milne J (2015) Wound bed preparation, the importance of rapid and effective debridement to promote healing. *Br J Nurs* 24(20): S52-8
- Ovens L, Irving S (2018) Advances in wound cleansing: an integrated approach. *Wounds UK* 14(1): 58-63
- Sterpione F, Mas K, Rippon M et al (2021) The clinical impact of hydroresponsive dressings in dynamic wound healing: Part 1. *J Wound Care* 30(1): 15-24
- World Union of Wound Healing Societies (2020) The role of non-medicated dressings for the management of wound infection. *Wounds International*. Available online at: www.woundsinternational.com
- Young T (2011) Reviewing the best practice in wound debridement. *Pract Nurs* 22(9): 488-92

This Made Easy supplement was supported by an educational grant from HARTMANN.

HARTMANN
+

© Wounds International 2021
Available from: www.woundsinternational.com

HydroClean®

**made
easy**



© Wounds International | April 2021 | www.woundsinternational.com

Case 1 (courtesy of John Schäfer)

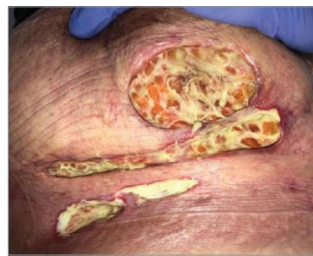

Figure 5a: Week 0

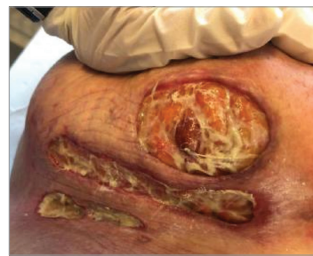

Figure 5b: Week 1

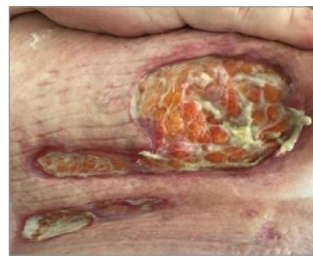

Figure 5c: Week 4

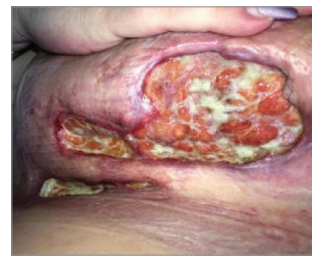

Figure 5d: Week 12

A 52-year-old female patient presented with pyoderma gangraenosum (PG), characterised by sudden onset of sterile pustules that rapidly develop into very painful ulcerations (Figure 5a), which can be challenging to treat. Successful management depends on treatment of the underlying disease, therefore, immunosuppressive therapy is necessary for wound healing as well as effective topical treatment.

The patient's wounds measured 2.5 x 7cm and 8 x 12cm and were causing the patient a lot of pain (VAS 7/10, during dressing change 9/10) and itching (VAS 9/10). Before introducing HydroClean®, different types of dressings were used, but were found to result in erythema, oedema and itching.

HydroClean® was selected in order to remove fibrin (Figure 5b; Figure 5c) and to reduce the characteristic pain of PG within a short period of time. In this case, the patient's pain was reduced 3-4 points after 2 weeks.

After 12 weeks of treatment with HydroClean®, there was a remarkable increase of granulation versus reduction of fibrin (Figure 5d). The moisturising, non-bonding and cooling effect of HydroClean® was crucial for reduction of pain and itching. In conclusion, HydroClean® is an effective topical treatment for patients with PG, in conjunction with a systemic immunomodulatory therapy – e.g. biologicals – initiated and monitored by an experienced physician.

Case 2 (courtesy of Emmanuelle Candas)

An 89-year-old bedridden patient with type 2 diabetes presented to the department with painful chronic varicose ulcers in both legs that had been present for 18 months, due to venous insufficiency. She is overweight, has advanced Alzheimer's dementia, and is undernourished. Before entering our geriatric rehabilitation department, she was living in her home in Paris. She was referred to the department from the 'Hospital at Home' unit (HAD – Hospitalisation à Domicile), who had been treating this patient's wounds for a few weeks. Dressing changes were becoming very difficult due to the patient's high pain levels. On presentation, she had numerous fibrinous and exudative wounds on both legs (legs with significant bilateral oedema, particularly on the left leg; Figure 6a and 6b).

The patient was initially very agitated when the time came to dress her wounds. This was likely related to wound pain and lack of understanding of the purpose of her dressing changes due to her dementia. After an effective analgesic premedication 1 hour before the treatment, we carried out the same protocol each day: washing of the wounds with soap and water, the application of HydroClean® and then an adapted venous compression.

As the days went by, fibrin reduced, leaving room for granulation tissue (Figure 6c). We thus transitioned to HydroTac® dressing to keep absorbing the remaining fibrin and exudate, while protecting the granulation tissue. By day 38, the wounds on both legs had reduced in size, with increased granulation tissue and epithelialisation (Figure 6d). The rapid autolytic debridement produced by HydroClean® allowed us to avoid mechanical debridement, considered dangerous in this patient with sometimes uncontrolled movements due to her dementia. The patient had become calmer during care thanks to the analgesics, thus facilitating dressing changes.

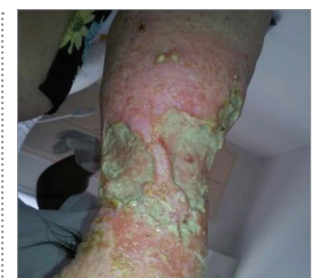

Figure 6a: Day 0 - right leg

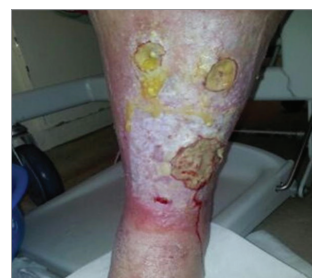

Figure 6b: Day 0 - left leg

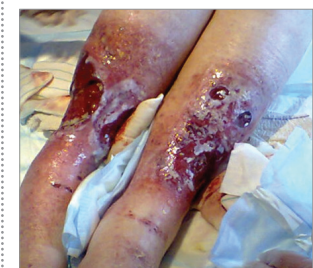

Figure 6c: Day 9 - 2 legs

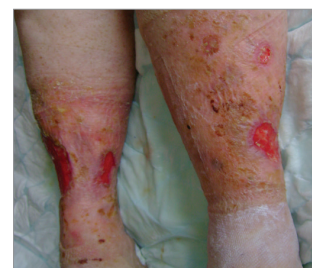

Figure 6d: Day 38 - 2 legs

When we consider the initial context of this patient – elderly bedridden patient with type 2 diabetes, overweight, advanced Alzheimer's dementia, undernourished and with venous insufficiency – the speed of healing of these wounds was very satisfactory. The ease of use of HydroClean® enabled rapid dressing changes, despite the large number of wounds, saving precious time for the caregivers and causing less stress to the patient.

Case 3 (courtesy of Jan Forster)

The patient was admitted to hospital due to a massive resting dyspnea, oedema of both legs, and an ulcer on the left leg. The patient's medical history included dilatative cardiomyopathy, cardiac decompensation, tachyarrhythmia with atrial fibrillation, and anticoagulant therapy. On presentation (Figure 7a), the wound measured 17 x 7cm, with a large volume of serous exudate with malodour (Flanagan Score 3). The wound bed was 75% fibrin, 25% pale granulation tissue, with undefined edge, no incipient epithelialisation and dry surrounding skin.

HydroClean® 10 x 17cm was selected as a primary dressing, with RespoSorb® 20 x 40cm as a secondary dressing, fixed with Peha-haft®, with dressing changes every 3 days. Irrigation was carried out with Ringer solution, and wound cleansing with sterile gauze and tweezers. Skin care was also initiated with 5% urea cream. Chronic venous insufficiency (CVI) as well as peripheral arterial disease (PAD) could be excluded by colour duplex examination; however, compression therapy to manage the oedema was not tolerated by the patient.

HydroClean® immediately began to dissolve the fibrin, and the wound showed signs of improved hydration and granulation (Figure 7b); malodour also decreased. After 10 days with 4 dressing changes, significant improvement of the wound environment could be observed (Figure 7c), including revitalisation and flattening of the wound edge, and epithelialisation from the wound edge. The wound bed was now 90% granulation tissue, with improved colour status, measuring 14 x 5cm. Exudate was reduced (Flanagan Score 2), along with malodour, which was no longer present. Over the next 10 days, exudate continued to decrease, so treatment was changed to HydroTac® dressing, with one dressing change per week.

HydroClean® was found to be a highly effective dressing, with cleansing, exudate absorption, autolytic debridement and infection risk reduction carried out by one product. The adhesive pads could be removed simply by wiping or using tweezers. In combination with RespoSorb®, treatment was effective and the planned dressing intervals could be safely adhered to.

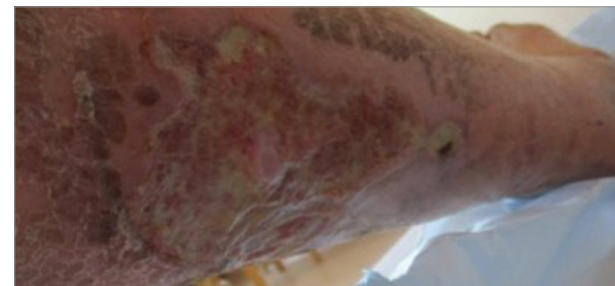

Figure 7a: Wound at presentation

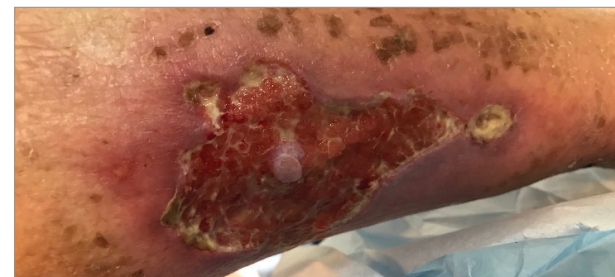

Figure 7b: After commencing treatment

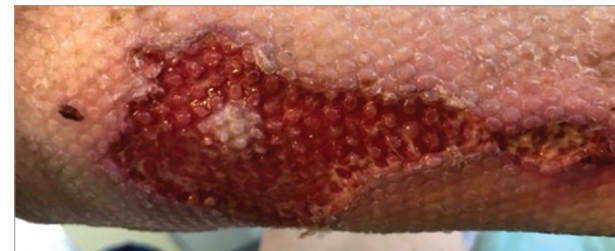

Figure 7c: After 10 days of treatment

Advantages of HydroClean®

- Suitable as a first-line dressing in a wide variety of wounds, not just those that are considered complex or hard-to-heal
- Supports wound bed preparation, enabling wounds to progress to healing
- Promotes autolytic debridement and removal of devitalised tissue and microorganisms
- Hydro-responsive, so can be used on wet or dry wounds
- Manages infection risk without contributing to AMR
- Easy to use by non-specialist staff and across care settings
- Easy to remove, reducing pain at dressing change
- No contraindications

clinical outcomes (Sterpione et al, 2021). HydroClean® can be used on a wide variety of wounds, enabling its selection as a first-line option in standard practice, not just those that are considered complex or hard-to-heal. Its ease of use means that it can easily be used by non-specialist practitioners, supporting use in a variety of care settings.

Conclusion

HydroClean® is a hydro-responsive, non-medicated wound dressing that has no contraindications, promotes autolytic debridement and manages infection risk without contributing to AMR. Studies have demonstrated that HydroClean® provides a safe and effective first-line option to remove barriers to healing and enable the wound to progress to healing. HydroClean® is a clear first-line option dressing, with potential use across the full healing continuum.

Introduction

If not appropriately managed, every wound has the potential to develop serious complications such as infection, and to become hard-to-heal (WUWHS, 2020). There is a clear need for a first-line dressing that can be used with confidence in a variety of different wound types and address potential factors that may develop and affect wound healing. As such, wound bed preparation is needed in all wounds that are expected to heal, to create conditions to optimise healing. In at-risk wounds, management of potential infection is also required.

HydroClean® is a safe and easy-to-use dressing that has been demonstrated to prepare and maintain the wound bed, reducing slough and necrosis. Its physical mechanism of action has the ability to disrupt biofilm where needed and to prevent at-risk wounds from 'regressing' into infection. It is important to note that HydroClean® is an easy-to-use and versatile dressing, designed as a first-line option to manage any wound that needs wound bed preparation or may be at risk of infection, instead of being reserved only for complex or hard-to-heal wounds.

The importance of wound bed preparation

Wound bed preparation represents an essential step in all wound management. A clean wound bed is a requisite for healing to progress. Devitalised tissue in the wound forms a physical barrier for wound re-epithelialisation, and this dead tissue can also become a reservoir for bacterial growth, increasing the risk of infection and complication (Atkin and Ousey, 2016). A structured, standardised method of wound bed preparation provides a pathway by which clinicians can aid more effective wound healing and remove any potential barriers to healing (Milne, 2015). As such, a structured framework should be used to facilitate wound bed preparation, such as the TIMERS principles (Atkin et al, 2019). As well as assessing the wound condition, the clinician should ensure that all potential barriers to healing are removed.

Potential presence of biofilm should also be a consideration in any wound bed preparation strategy. Reducing the presence of

biofilm in a wound may tip the balance in favour of healing; if biofilm is suspected and may result in delayed or compromised healing, it should be treated proactively by:

- Breaking up and removing the biofilm, through active cleansing and/or appropriate debridement
- Reducing biofilm reformation by decreasing the microbial burden left in the wound through the use of an appropriate dressing.

A proactive approach to treatment recognises that there is no one-step solution for treatment of biofilm, but aims to reduce bioburden and prevent its reconstitution (Ovens and Irving, 2018).

Hydro-responsive wound dressings

Hydro-responsive wound dressings – such as HydroClean® and HydroClean® advance – are dynamic dressings that can deliver or absorb moisture as required, depending on the environmental fluid balance. Hydro-responsive wound dressings are classified as non-medicated wound dressings, able to manage infection without using any active antimicrobial agent. Instead, bacterial load is reduced via physical means, including:

- Removing the devitalised tissue within which bacteria may reside, and which are outside the normal host immune response surveillance system
- Maintaining a low bioburden level by the absorption, sequestration (taking temporary possession), retention and removal of bacteria at the wound site (WUWHS, 2020).

The process of sequestration is used, whereby exudate, debris and bacteria are drawn into the core of the dressing and held within a dressing matrix. The bacteria are physically bound within the core of the dressing material, and so they can then be easily removed along with the dressing when it is changed (WUWHS, 2020).

There are significant benefits to using non-medicated wound dressings; in particular, these dressings enable reductions in the wound's bioburden without contributing to antimicrobial resistance (AMR). AMR is a severe and growing issue in wound care, as the use of topical antimicrobials (e.g. creams or dressings) or antibiotics (medication) to treat wound infection has (among other causes) resulted in increasing numbers of species of bacteria becoming resistant to treatment. In order to reduce this problem, alternative means of treating infected or at-risk wounds need to be used. Therefore, physical means of removing bioburden – such as non-medicated wound dressings – should be used wherever possible (WUWHS, 2020). As they do

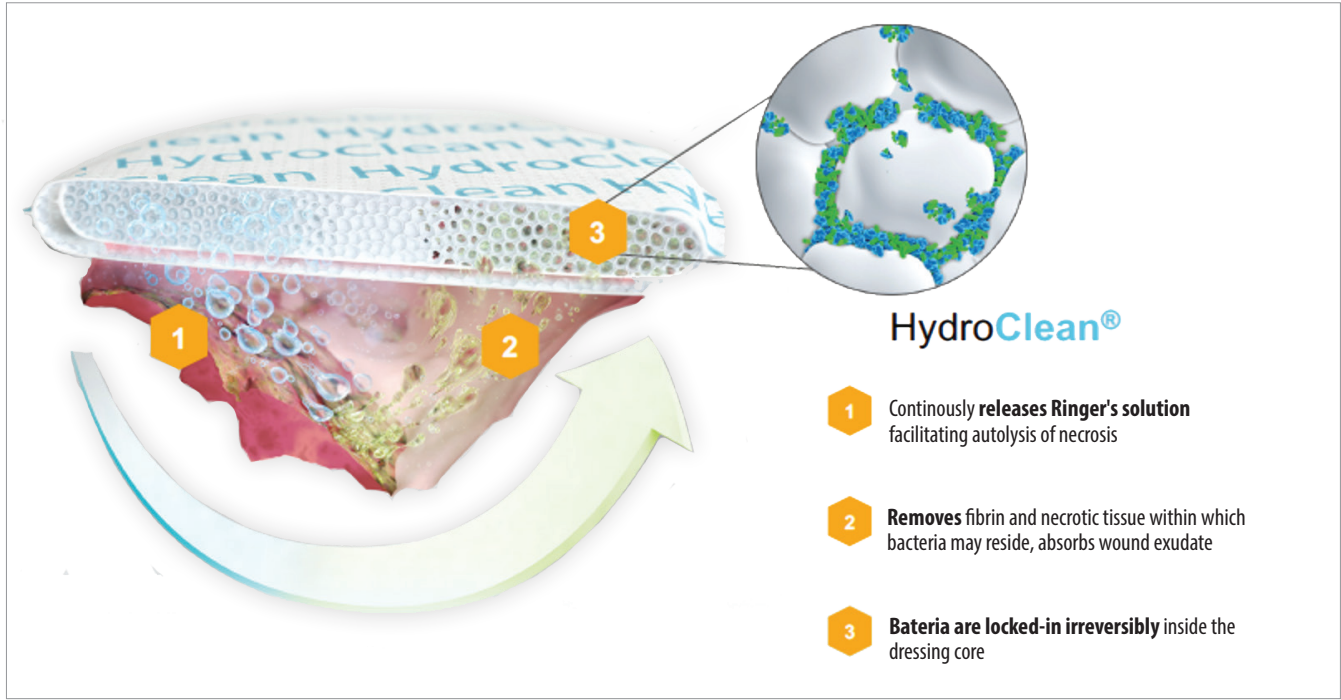


Figure 1: HydroClean®'s physical mechanism of action

not contain active pharmaceutical substances, non-medicated wound dressings, such as hydro-responsive wound dressings, are suitable in a wide range of wound types. Except for possible intolerance to the dressing components, there are no major contraindications and the dressings can be used as a first-line option for wounds where risk of infection may be an issue.

HydroClean®

HydroClean® is a non-medicated, hydro-responsive wound dressing. This means that HydroClean® enables wound cleansing and debridement, promoting the development of healthy granulation tissue, while also addressing moisture issues (donating moisture if the wound is dry, or absorbing exudate if the wound is wet). The dressing is made up of a soft and conformable pad, which contains superabsorbent polyacrylate (SAP) at its core; the SAP particles are pre-activated with Ringer's solution – see Figure 1.

HydroClean®'s mechanism of action

Optimal mechanism of action involves multiple steps taking place in a coordinated manner: debridement (disruption of devitalised tissue and microorganisms), absorption (uptake of devitalised

Key properties of HydroClean® (adapted from WUWHS, 2020)

- Does not contain any active antimicrobial agent – Ringer's solution is released to help soften devitalised tissue and cleanse the wound
- Supports autolytic debridement and stabilises the wound environment
- Inactivates excess MMPs, inducing progress to granulation tissue formation
- Ideal for infected wounds or wounds at risk of infection as HydroClean® effectively eradicates bacteria by physical ways, while not inducing bacterial resistance

tissue and microorganisms), sequestration (devitalised tissue and microorganisms drawn in and locked away), retention (devitalised tissue and microorganisms held and immobilised) and removal (devitalised tissue and microorganisms removed within the dressing), while each of these mechanisms is still able, individually, to reduce bacterial numbers (Figure 2). HydroClean® works by facilitating these key steps (WUWHS, 2020).

1. Debridement

Debridement results in the disruption of devitalised tissue

containing a large proportion of the wound's bacterial load, and this disruption aids in subsequent removal of the bioburden, as evidenced in recent experimental studies. HydroClean® can deliver or absorb moisture depending on the environmental fluid balance — wound debridement is promoted by the softening and detachment of the devitalised tissue by the availability of the Ringer's solution. Clinically, such dressings have been shown to be very effective in reducing signs and symptoms of infection (WUWHS, 2020).

2. Absorption of wound exudate and bacteria

Exudate management is a critical step in providing an appropriate environment for healing to take place. Too little or too much exudate will have a negative impact on the wound and the patient's wellbeing. Due to its core containing SAP (superabsorbent polymers), HydroClean® absorbs slough and exudate, and specifically binds bacteria and proteases contained in the wound exudate, thus blocking their negative effect on healing. HydroClean® may be used in dry wounds to donate moisture and in exuding wounds to absorb the excessive exudate.

3. Sequestration

The term sequestration comes from the Latin word *sequestrare*, which essentially means taking something and locking it away. The term has been used to describe the mechanism whereby devitalised tissue and microorganisms are drawn into the core of the dressing and held within a wound dressing matrix in the wound environment without killing them, thus reducing the risk of further debris being left in the wound (i.e. avoiding endotoxins' additional damaging effects).

4. Immobilisation and retention

The ability of materials within the dressing to aid in the absorption and sequestration of bacteria indicates that these dressings physically remove bacteria from the wound, thus reducing bacterial load without any bacterial killing. Bacteria that are physically retained by adherence to the dressing material and within the confines of a wound dressing are easily removed when the dressing is changed. Repeated application and removal of these dressings is accompanied by a regular reduction in the level of bacteria found within the wound bed.

Evidence for HydroClean®

A clinical study conducted for up to 20 weeks, assessing the use of HydroClean® according to several clinical parameters (wound size, exudate production, tissue type), found that a positive wound healing trajectory was seen, with a 44% reduction in mean wound area

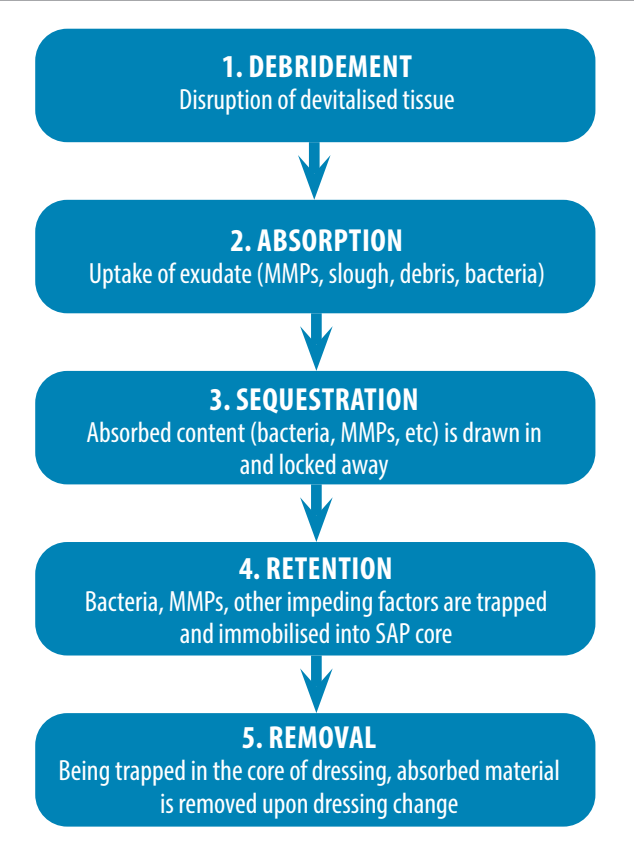


Figure 2: Mechanism of action of non-medicated wound dressings

($p=0.0069$; Sterpione et al, 2021). The study also found that pain scores were reduced, with patients reporting low levels of pain experienced at and between dressing changes; both patients and caregivers rated the dressing positively in terms of pain and atraumatic dressing change, ease of use, acceptability and assessment of wound response to HydroClean® (see Figure 3 and 4 for further information).

All of the wounds assessed in this study (a mixture of chronic and acute wound types of varying severity) required removal of devitalised tissue to progress to healing, and the study found HydroClean® to be highly effective in preparing a clean wound bed in order for the wound to progress. An alternative dressing could then be used to support subsequent clinical challenges. Therefore, HydroClean® was found to be a highly versatile dressing that is suitable as a first-line treatment in all wounds that may require wound bed preparation and infection control (Sterpione et al, 2021).

A recent exploratory study examined the wound healing response of venous leg ulcer wounds treated with HydroClean for

Figure 3: Caregiver's assessment of wound response to HydroClean® (Sterpione et al, 2021)

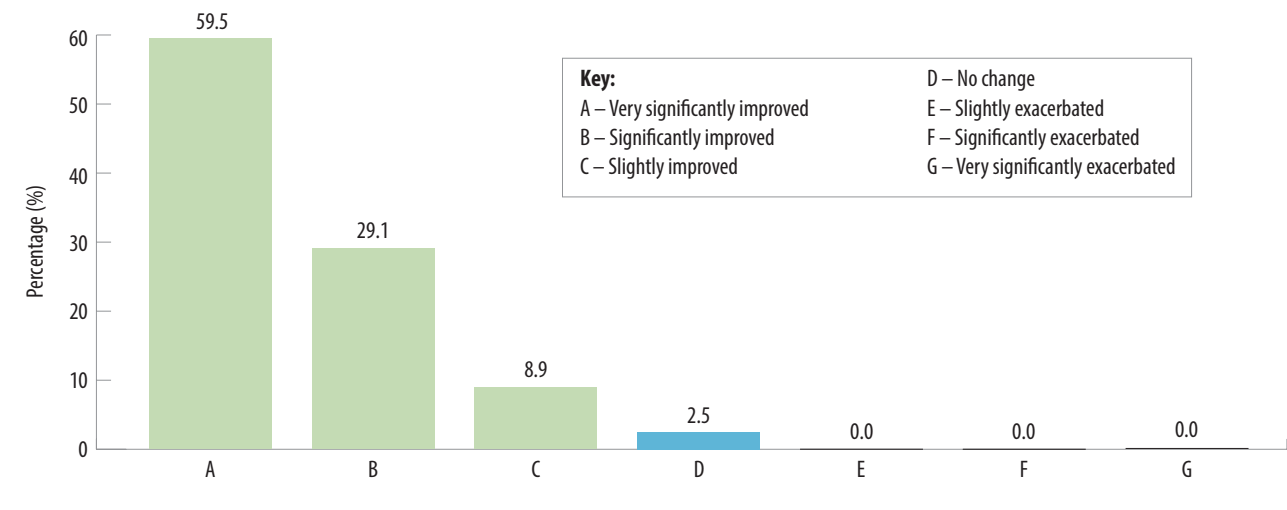
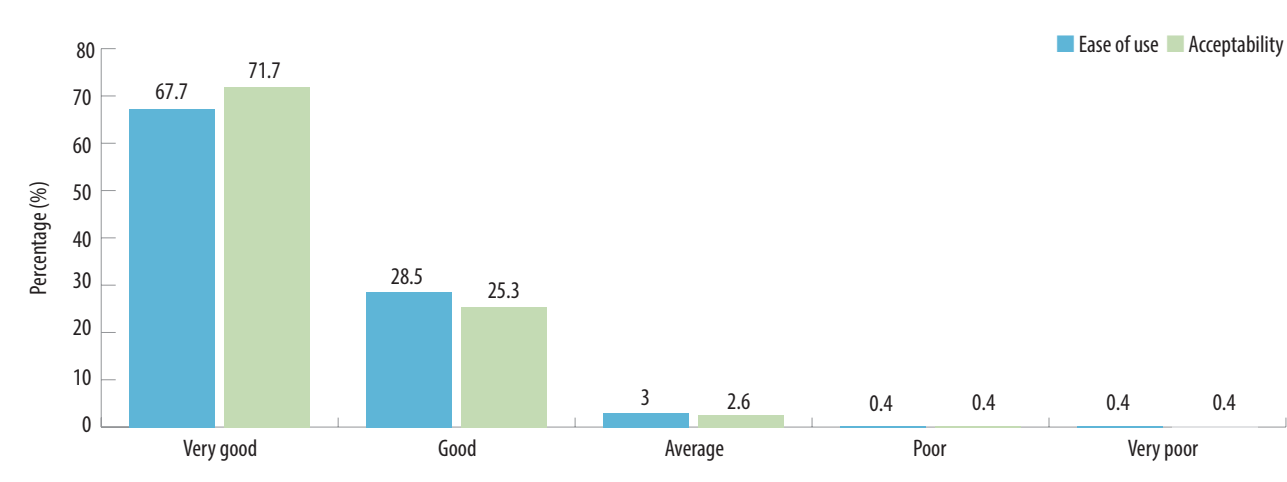


Figure 4: Caregiver assessments of ease of use and acceptability of HydroClean® (Sterpione et al, 2021)



12 weeks. In this study, the composition of the wound exudate was compared with wound exudates of acute wounds (split-thickness donor sites). The venous leg ulcer cohort had a large proportion of wounds with low healing tendencies, such as a wound area of more than 10cm² and a duration of more than 6 months. The results, publication pending (Mikosiński et al, 2021), show a robust response with relative wound area reduction reaching 48.9% ± 51.9%, and 61.4% of the patients achieved relative wound area reduction of ≥40%. The analysis of the biochemical markers in the wound exudates saw a significant change in the expression pattern of the biomarkers during the first 14 days. The pattern of the biochemical markers in the venous leg ulcer exudates started to resemble those

acute wounds at the height of granulation tissue formation and epithelialisation. This pattern was stable throughout the remaining 10 weeks of the study and suggests that HydroClean rapidly changed the biochemical marker pattern in this type of chronic wound to a pattern observed in acute healing.

Benefits in practice

There are overall benefits to the practitioner in selecting a versatile and easy-to-use dressing as a first-line option in all suitable wounds. The versatility and lack of contraindications means that the process is simplified, leading to standardisation of practice that improves